



Radiology Techniques

Department

The Radiological Anatomy

Lecture 3

The stomach & duodenum and small intestine

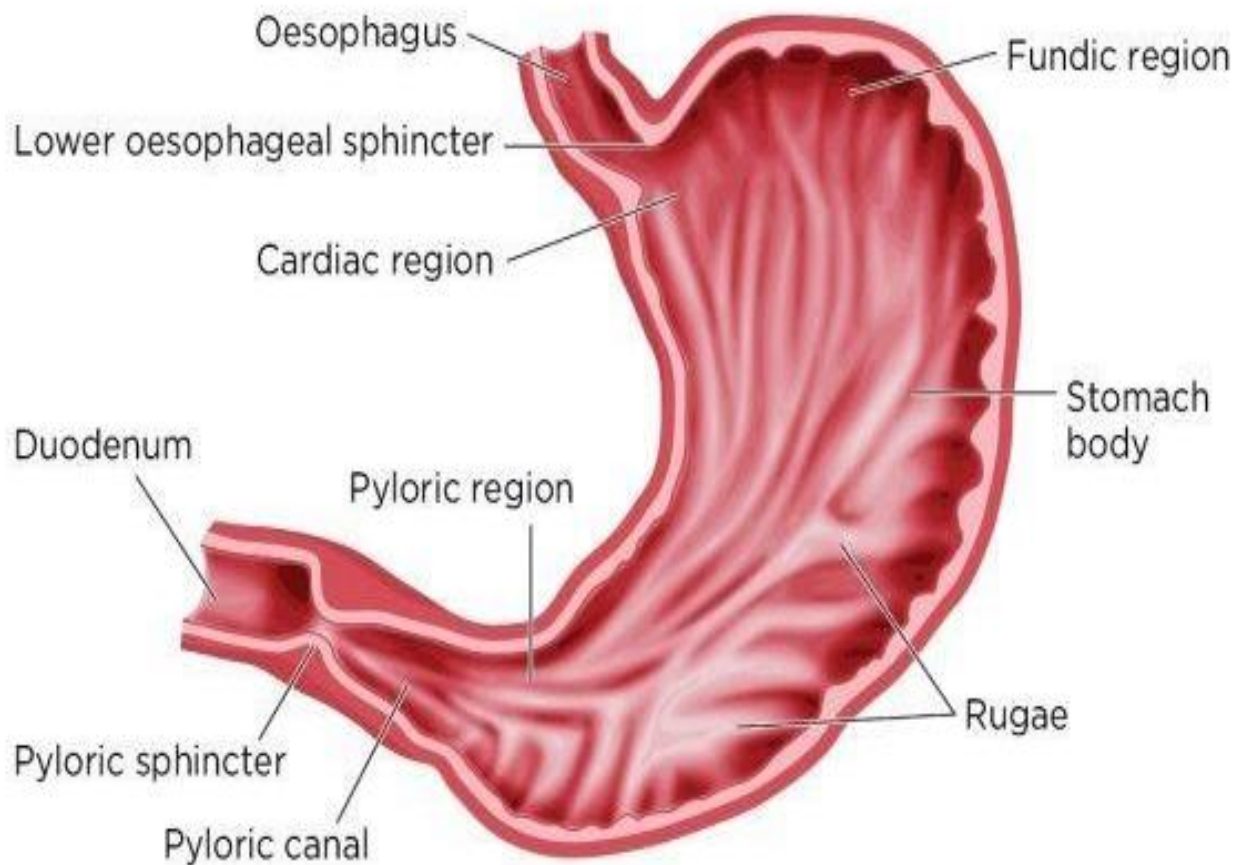
By

MS.c Zeyad Tareq & MS.c Salman Mohammed

3rd Stage

- The stomach is J shaped but varies in size and shape
- It has 2 orifice cardiac sphincter and pyloric sphincter
- It has 2 curves 1- **the greater curve**
2- **the lesser curve**
- The stomach can be divided into 3 parts(regions):
- Upper → the **fundus**
- Middle → the **body of stomach**
- Lower → the **pyloric region**

Fig 1. **Regions of the stomach**



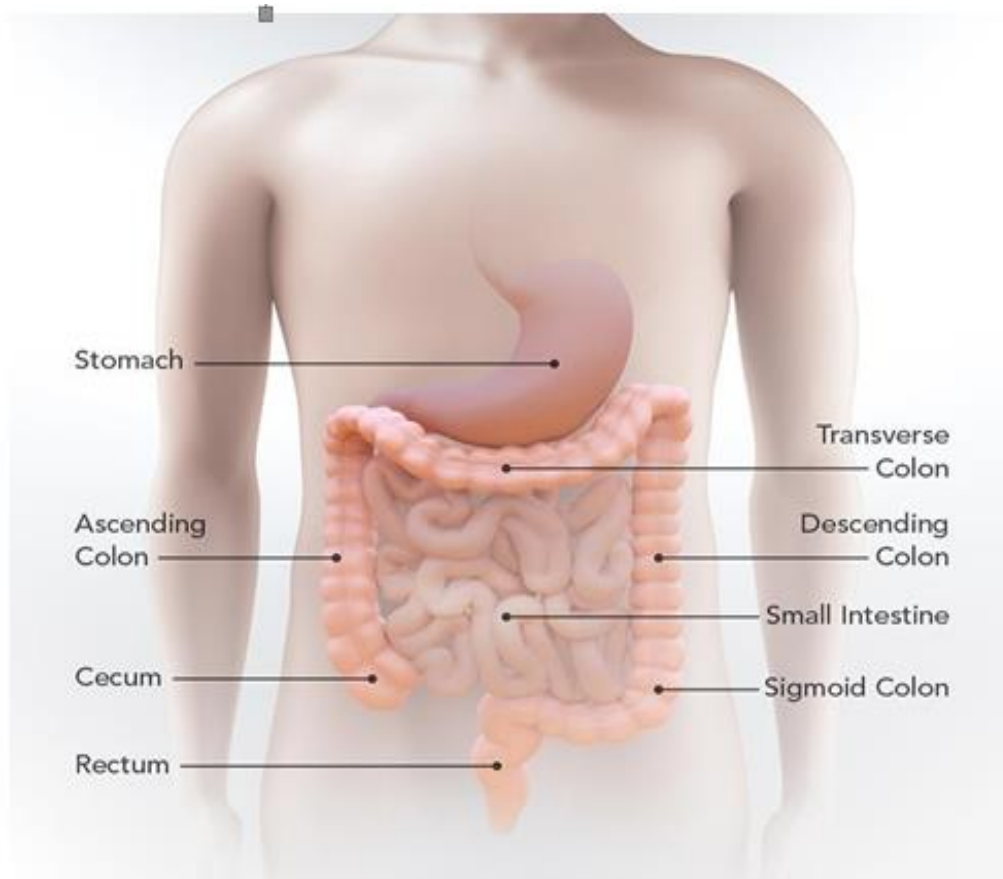
Anterior to the stomach

- The upper part of the stomach is covered by
 1. left lobe of the liver
 2. left diaphragm
- The remainder of the stomach by anterior abdominal wall

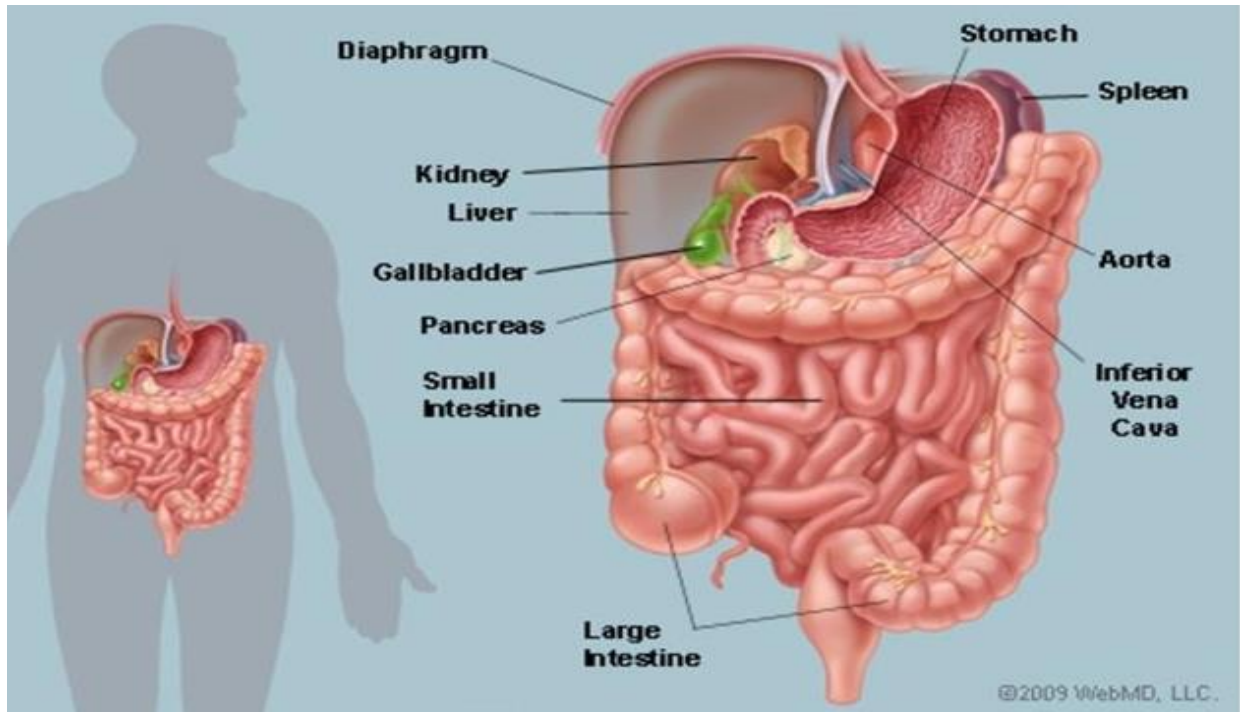
Posterior of the stomach

- Posteriorly the stomach is covered by peritonium (lesser sac)
- Organs lies posterior to the stomach are:
 1. Pancreas
 2. spleen
 3. kidney
 4. Diaphragm

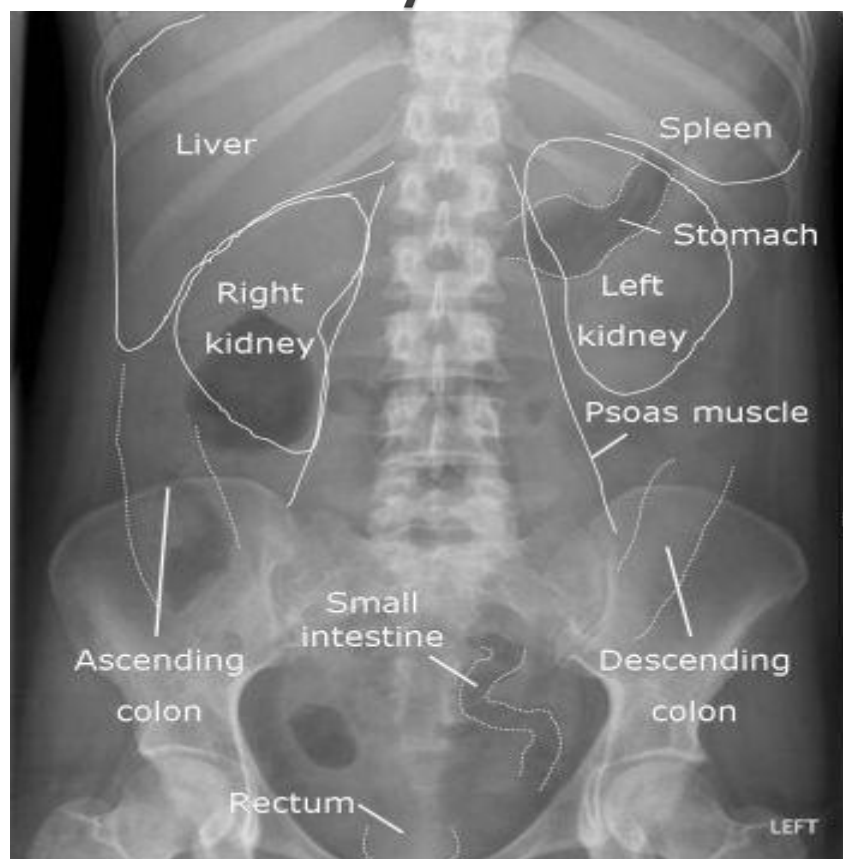
Inferior to the stomach is the transverse colon



The stomach in relations to other abdominal organs

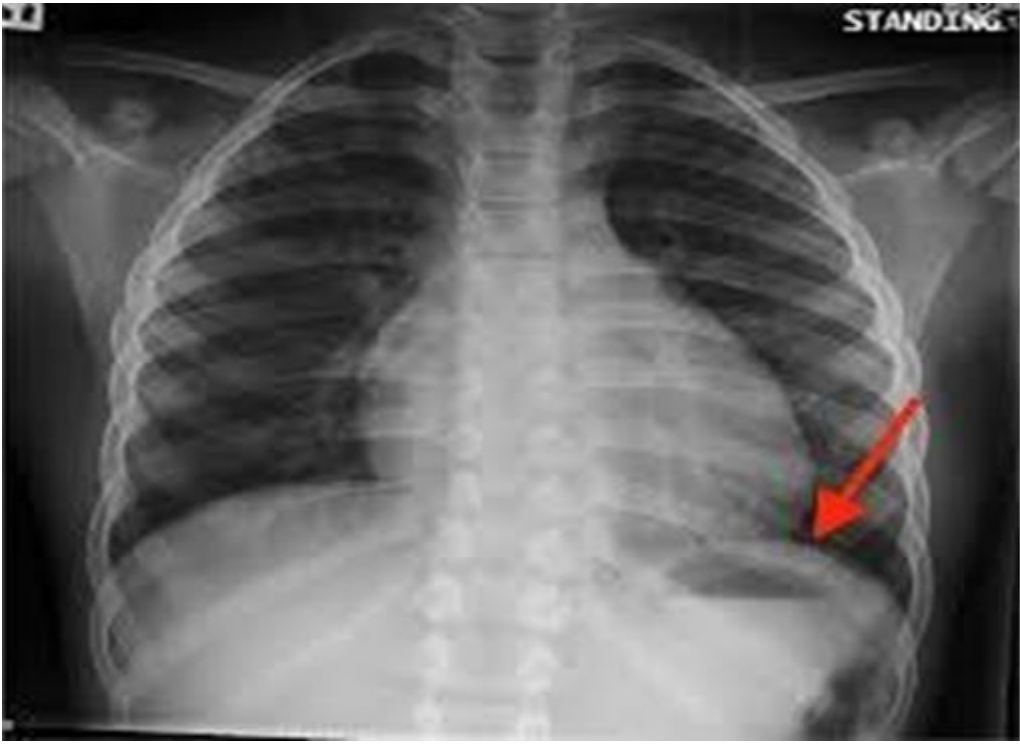

Surface anatomy of the abdomen



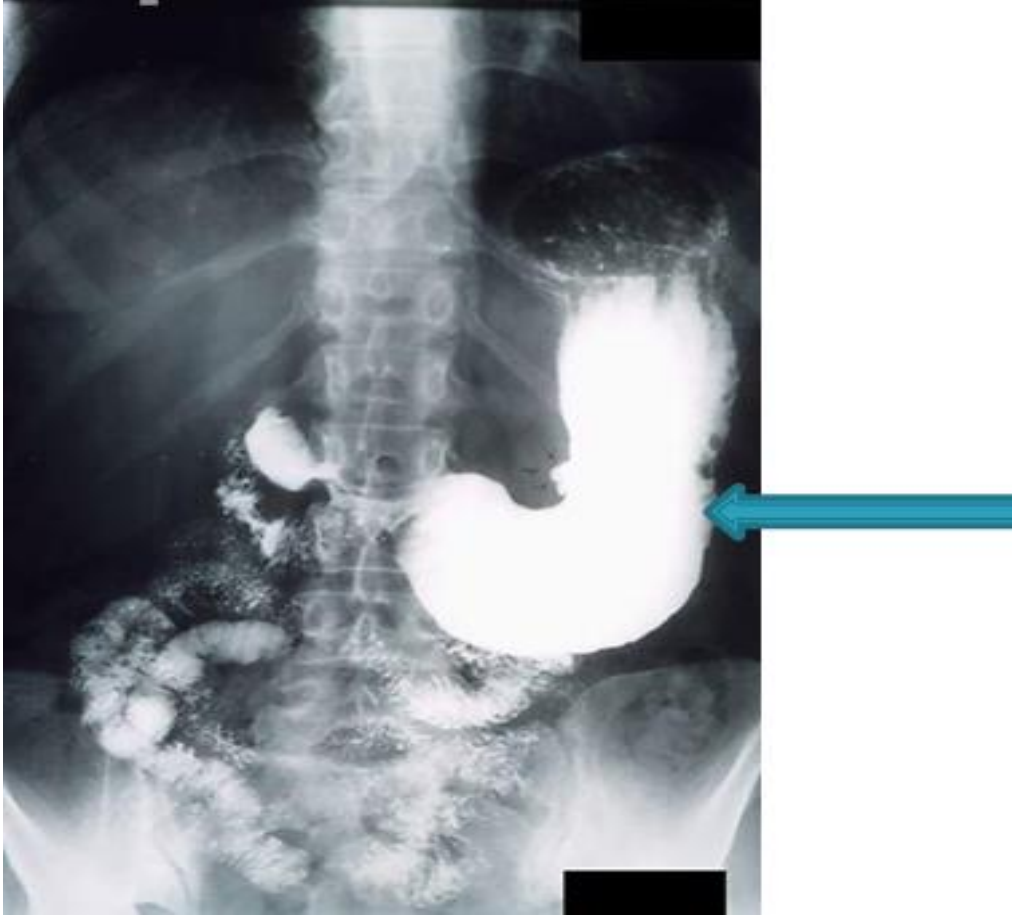
Chest Xray

the red arrow refer to the stomach



Stomach barium meal

blue arrow refer to the stomach



The duodenum

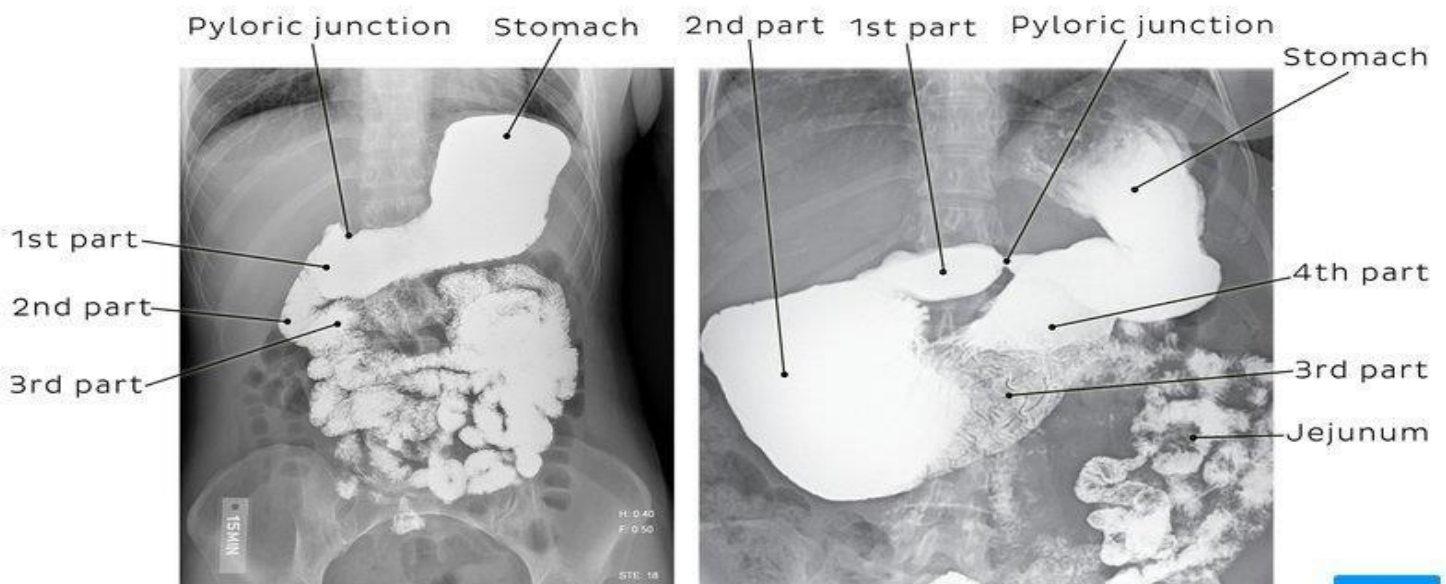
- Extends from the pylorus of the stomach to the duodeno-jejunal flexure
- It is a C shaped where the head of pancreas embedded
- Devided into 4 parts:

First part or superior part (2 cm) **Second part** or descending part (8 cm)

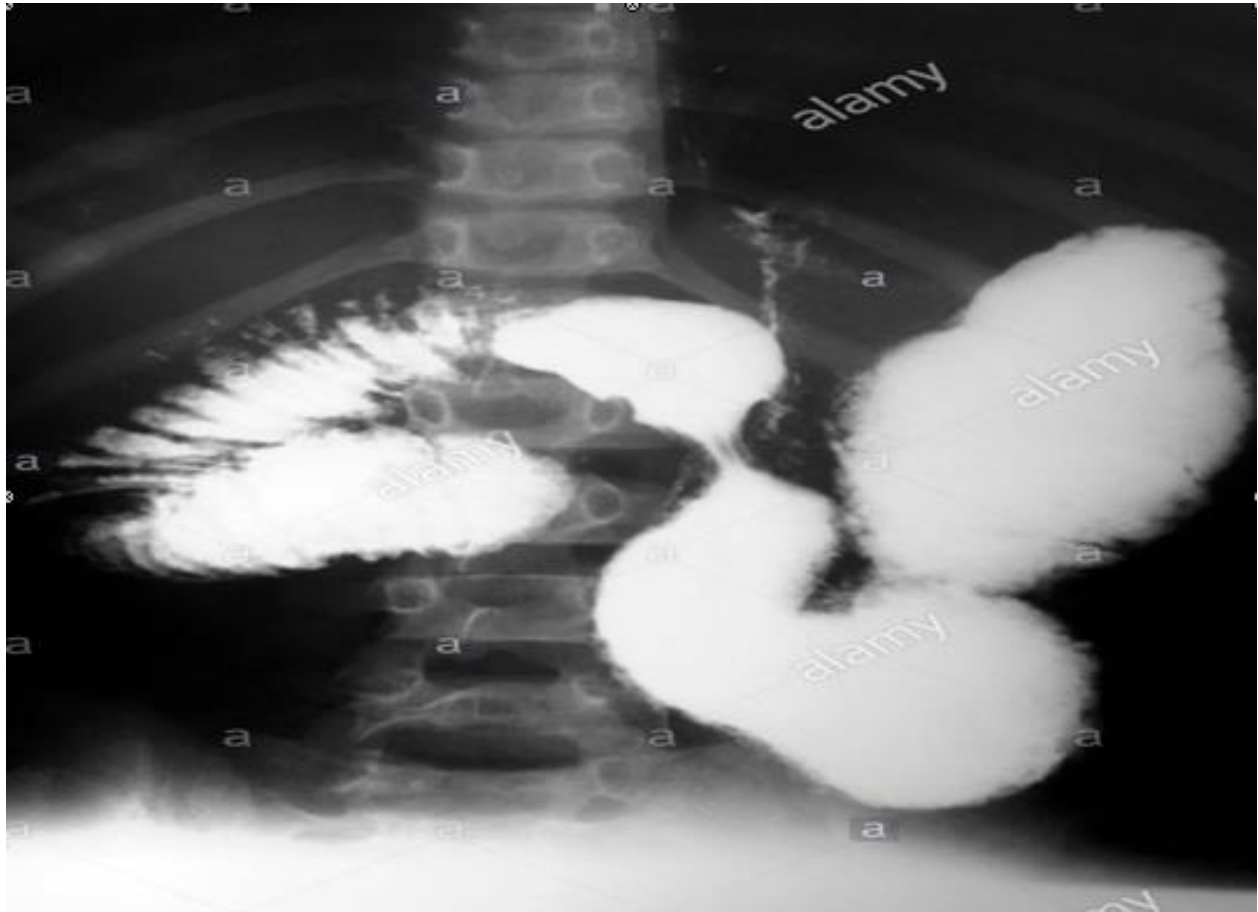
Third part or horizontal part (8 cm) **Fourth part** or ascending part (4 cm)

The duodenum

- The 1st part (duodenal bulb or cap) of the duodenum is at level of L1 lumbar vertebra
- The 2nd part at level L2 lumbar vertebra
- The 3rd part at level L3 lumbar vertebra
- The 4th part at level of L2 lumbar vertebra



Barium meal showing the stomach and the duodenum



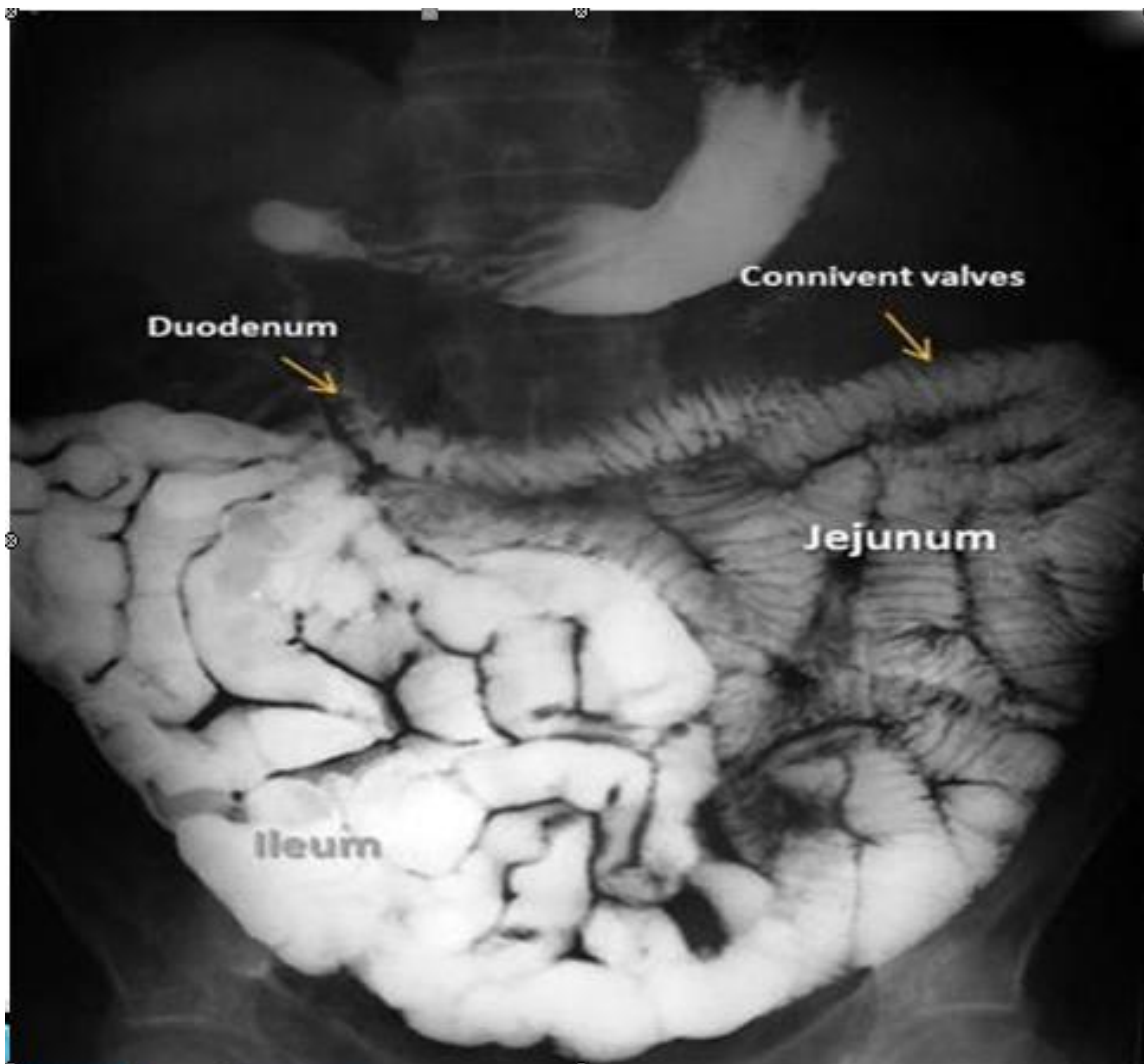
The small intestine

- Starts at the duodenojejunal junction and ends at the ileocecal junction
- From 3-10 meters (average of 6 meters)
- The proximal 2/5 is called the jejunum
- The distal 3/5 called the ileum
- The boundary between the 2 is not well defined

The small intestine

- The jejunum found at leftupper abdomen
- The ileum found at lower abdomen and right iliac fossa

Barium follow through



Thank You!